

AUA UPDATE SERIES

Office Evaluation of the Subfertile Male

Bruce R. Gilbert, M.D., Ph.D.
Clinical Assistant Professor of Surgery (Urology)
The New York Hospital-Cornell Medical Center

Peter N. Schlegel, M.D.
Assistant Professor of Surgery (Urology)
The New York Hospital-Cornell Medical Center and
Staff Scientist

and

Marc Goldstein, M.D.
Associate Professor of Surgery (Urology) and
Director, Male Reproduction and Microsurgery Unit
The New York Hospital-Cornell Medical Center and
Staff Scientist
The Population Council, Center for Biomedical Research
New York, New York 10021

Lesson

9


Volume XIII

This CME activity was planned and
produced in accordance with the
ACCME Essentials.

© 1994 American Urological Association, Inc.
Office of Education
Houston, Texas

Editor-in-Chief
Thomas P. Ball, Jr., M.D.
San Antonio, Texas
Assistant Editor
Donald E. Novicki, M.D.
Scottsdale, Arizona
Coordinator
Gwen Montano
Houston, Texas

Editorial Board
David M. Barrett, M.D.
Rochester, Minnesota
Charles J. Devine, Jr., M.D.
Norfolk, Virginia
John P. Donohue, M.D.
Indianapolis, Indiana
John W. Duckett, Jr., M.D.
Philadelphia, Pennsylvania



William R. Fair, M.D.
New York, New York
Robert P. Gibbons, M.D.
Seattle, Washington
Warren W. Koontz, Jr., M.D.
Richmond, Virginia
Winston K. Mebust, M.D.
Kansas City, Kansas

Jerome P. Richie, M.D.
Boston, Massachusetts
E. Darracott Vaughan, M.D.
New York, New York
R. Dixon Walker, M.D.
Gainesville, Florida
Alan J. Wein, M.D.
Philadelphia, Pennsylvania

Office Evaluation of the Subfertile Male

Bruce R. Gilbert, M.D., Ph.D., Peter N. Schlegel, M.D., and Marc Goldstein, M.D.

Significant advances have been made in our ability to evaluate and treat the subfertile male. We now appreciate that subfertility is a couples dilemma. This is in part due to our increased knowledge of factors associated with male subfertility as well as recent advancements in tests and diagnostic equipment. In addition, the availability of sophisticated reproductive technology has enabled us to offer even azoospermic patients the opportunity to father a biologic child.

Male factor is the primary or contributing cause in 40 to 60 percent of the couples presenting for a fertility evaluation. Therefore, the male and female need to be evaluated concurrently.

It is no longer sufficient to state that the male is "normal" because the semen parameters are "within the normal range." **It is the number of progressively motile, morphologically normal and functional normal spermatozoa that are important. In addition, these spermatozoa need to be in a seminal fluid of appropriate volume and composition. Then, this mixture of spermatozoa and seminal fluid must be placed in a physiologically and anatomically normal female genital tract.** It is the ability to precisely define these parameters together with increased awareness of factors altering these parameters, that allow us to diagnose and ultimately treat an increased number of male factor disorders.

The following examples selected from our patient population highlight some of these disorders:

A 30-year-old male presents with fructose positive azoospermia, a normal hormonal profile, palpably absent vasa and a normal *bilateral* testis biopsy. Surgical exploration and retrieval of fluid from the remnant epididymis was used for microinsemination of oocytes retrieved from his wife. The couple now has a healthy one-year-old son. Sophistication of assisted reproductive technologies has refined the definition of male sterility. **In 1994, fertility is possible as long as mature spermatozoa are present at the level of the rete testis/efferent ductules.**^{1,2}

A 37-year-old male presents four years after the birth of his first child with a year and a half of secondary subfertility. He had been treated for prostatitis two years prior. Transrectal ultrasound demonstrated enlarged seminal vesicles with an increased echogenicity at the level of the ejaculatory ducts bilaterally. Preoperatively his total sperm count was 3.5 million with seven percent motility in a volume of 0.35ml. Transurethral resection of the ejaculatory ducts resulted in an increase to 92 million total sperm and 53 percent motility with an increase in seminal fluid volume to 1.80ml. A spontaneous pregnancy resulted three months postoperatively. The concept of 'partial obstruction' has evolved. **Transrectal ultrasound has become an important adjunct to the clinical examination.**

A pediatrician with over 200 million sperm and good progressive motility but with greater than 20 percent tapered heads presented with two years of secondary subfertility. His wife had had a normal evaluation. Ligation of his large left varicocele resulted in a doubling of his total sperm count and a four and one half times increase in the number of progressively motile and morphologically normal spermatozoa (44 million preoperatively to 206 million postoperatively). A pregnancy occurred seven months postoperatively. **Over 80 percent of men with secondary subfertility have been found to have varicoceles that impair the couple's fertility.**^{3,4}

In this lesson we will present a contemporary overview of the

evaluation of male factor subfertility. Particular emphasis will be placed on new diagnostic techniques readily available to the practicing urologist.

CLINICAL EVALUATION

Anatomic and Physiologic Considerations⁵

Testicular sperm production and normal sex accessory gland function in the male is possible only in an appropriate hormonal milieu. Pulsatile release of GnRH from the hypothalamus stimulates LH and FSH release by the pituitary. These gonadotropins are responsible for stimulation of testosterone production and spermatogenic function, respectively. The average testicular volume is ≥ 20 cc in healthy young men and decreases in elderly men. Normal length of the testis is greater than 4.0 cm. The testis contains seminiferous tubules and interstitial cells. The tubules are segregated into regions by connective tissue septa. The seminiferous tubules are long V-shaped tubules, both ends of which usually terminate in the rete testis. **Measurement of testicular size is critical in the evaluation of the infertile man, since seminiferous tubules (the spermatogenic region of the testis) occupy approximately 80 percent of testicular volume.** A rough estimate of spermatogenic cell capacity is thus provided by assessment of testicular size. Testicular size can be estimated clinically by use of an orchidometer or measured using scrotal sonography. Testicular consistency is also of value in determining fertility capacity. **A soft testis is likely to reflect impaired spermatogenic components.**

The seminiferous tubules drain toward the central superior and posterior regions of the testis, the rete testis. The rete coalesces in the superior portion of the testis, just anterior to the testicular vessels, to form 5 to 10 efferent ductules. These efferent ducts leave the testis and travel a short distance to enter the head, or caput region of the epididymis. The efferent ducts coalesce in a somewhat variable pattern within the caput epididymis to form a single epididymal tubule. Clinically, palpable induration along the course of the epididymis should raise the suspicion of epididymal obstruction.

Anatomically, the epididymis can be divided into three regions: the caput, the corpus, and the cauda epididymis. However, these anatomical divisions have been defined based on findings in animals, not in humans. The human epididymal epithelium is relatively homogeneous as viewed under the microscope, and grossly, the epididymis does not have the same distinct gross anatomical subdivisions that are easily seen in the rat, rabbit, and other animals. Unfortunately, there is little information available regarding the functional diversity of these three regions of the human epididymis. The data that exist on human epididymal function are almost entirely derived from observations of men after relief of chronic epididymal obstruction.

Protein secretion and the storage capacity of the epididymis has been shown to be profoundly affected by changes in epididymal temperature in animals. Some have even postulated that the driving force for evolution of the scrotal location of testes is to have the epididymis maintained at a temperature below that of the body core temperature in the scrotum. Whether the functions of the human epididymis are similarly affected by body temperature is unknown. The potential influence of temperature on epididymal function in man may be an important

consideration in explaining the relationship between varicocele and male infertility. **If temperature significantly affects human epididymal function, then it could explain improvements in semen parameters that may occur less than three months (one full cycle of spermatogenesis) after varicocele ligation.**

The rate of transport of fluid through the vas deferens is not known in the human. Just prior to ejaculation, the testes are brought up close to the abdomen and fluid is rapidly transported through the vas deferens toward the region of the ejaculatory ducts and subsequently into the prostatic urethra. The ejaculatory ducts enter the prostatic urethra just lateral to the verumontanum.

The artery to the testis is specialized in that it is highly coiled and intimately associated with a network of anastomotic veins that form the pampiniform plexus. The counterflowing vessels are separated only by the thickness of their vascular wall in some areas. This vascular arrangement facilitates the exchange of heat and small molecules, including testosterone. The transport of testosterone is a concentration-limited, passive diffusion process in men. The counter-current exchange of heat in the spermatic cord provides blood to the testis that is 2 to 4°C lower than rectal temperature in the normal individual. A loss of the temperature differential is associated with testicular dysfunction in humans with idiopathic infertility, as well as varicocele and cryptorchidism. Whether elevated testicular temperature causes or is simply a reflection of testicular dysfunction is unknown. Only the association between elevated testicular temperature and seminiferous failure has been demonstrated.⁶

The venous system is somewhat unique because the spermatic veins are thin-walled, poorly muscularized, and lack effective valves except at the inflow points into the inferior vena cava or the renal vein. The right spermatic vein usually drains into the vena cava. The left spermatic vein drains into the left renal vein. The differential anatomy of the left and right spermatic veins is thought to explain, at least in part, the higher prevalence of varicoceles on the left side. The exact mechanism by which varicoceles cause infertility is unknown. In animal models, varicoceles are associated with increased blood flow to the testis and increased interstitial fluid in the testis. These two findings may impair regulation of testicular temperature and decrease intratesticular concentrations of testosterone or other local factors important for spermatogenesis.

Clinical History

The history and physical examination of the infertile man should be directed toward detection of factors associated with impaired fertility in men. Use of a questionnaire facilitates the accumulation of necessary information in an expeditious manner. The questionnaire that we use has been previously published.⁷ The history should initially include classification of the prior fertility of the man. Has he previously contributed to a pregnancy in this partner or a previous partner? After delineation of primary or secondary infertility for the man, a careful sexual history should be obtained to confirm that the couple is having sexual intercourse with timing consistent with the achievement of conception. An understanding of the menstrual cycle and the importance of appropriate frequency of intercourse, without use of anti-sperm agents such as lubricants and avoidance of douching after intercourse, is important for the couple. Brief assessment of the infertility evaluation of the female partner should be obtained so that inappropriate intervention is not entertained for the man when fertility is not possible for the couple because of an irreparable female factor.

A history directed toward the general physical health of the

man should then be performed, with specific attention to factors that impair male fertility potential. Specific childhood illnesses associated with infertility include cryptorchidism and postpubertal mumps orchitis. The timing of pubertal landmarks and characteristics of secondary sexual development should be noted (onset of axillary and pubic hair, start of shaving, density of beard relative to male siblings). Operative intervention on the bladder neck (including YV plasty for UTI or vesicoureteral reflux) may be associated with retrograde ejaculation. Retroperitoneal lymph node dissection for testis tumor and other retroperitoneal surgery may disrupt sympathetic pathways necessary for emission and antegrade ejaculation. Oral sympathomimetic drugs may allow the return of emission or conversion of retrograde to antegrade ejaculation in up to 50 percent of patients. Other men may be successfully treated with electroejaculation, if irreversible testicular dysfunction is not present.

Medical conditions such as diabetes or hypertension may affect sexual performance or testicular function. Diabetes can affect the sympathetic action necessary for bladder neck closure and antegrade ejaculation. Again, sympathomimetic drugs or electroejaculation may be used for treatment of these patients. Any generalized constitutional insult causing fever or viremia may impair testicular function. The effects of this insult can be detectable for up to one to three months after the infection.

Medications may also impair testicular or sexual function. A detailed history of all medications is needed to assess their potential effect on fertility. Sulfasalazine, cimetidine, and nitrofurantoin have all been documented to impair testicular function for some men. Although antibiotics are necessary to treat infections that result in pyospermia and adversely affect fertility potential, long-term treatment of men with some antibiotics may also impair fertility, at least during the period of treatment. Androgenic drugs, such as anabolic steroids, can inhibit function of the hypothalamic-pituitary-testicular axis, leading to hypogonadism. Other drugs, including alcohol, nicotine, and marijuana may adversely affect testicular function, directly or indirectly.

Physical Examination

Physical examination of the infertile man should be complete and thorough, since any significant medical condition may adversely affect testicular function. A warm room is critical to allow adequate relaxation of the scrotum to facilitate examination of the scrotal contents. A global assessment of androgen action should initially be performed. Temporal balding requires DHT action. Normal axillary and pubic hair distribution are related to androgen action. Gynecomastia results from excessive estrogen action or an imbalance between androgens and estrogens. **The general appearance of men with recognized syndromes (e.g., Kallman's syndrome: anosmia, lack of sexual secondary characteristics, long arms, short fourth metacarpals, etc.) should be considered, although a definitive diagnosis of idiopathic hypogonadotropic hypogonadism requires serum hormone evaluation.**

Specific attention to the genitourinary examination is necessary. The penis should be evaluated for lesions, curvature, and Peyronie's plaques. Location of the urethral meatus should be noted, and assessed relative to the ability of the patient to place the ejaculate deep within the vagina during intercourse for hypospadiac men. The abdomen should be palpated for abdominal masses and the inguinal regions closely inspected for scars.

The scrotal exam is most easily performed in a warm room. Initially the patient is examined supine. This causes varicoceles,

if present, to collapse. The consistency of the testis can be best evaluated in this position, including the presence of any testicular masses. Testicular examination should carefully assess the volume and consistency of the testis, since the testicular volume is predominantly composed of seminiferous tubules. Testis tumors are often associated with excessive aromatase activity and infertility. Induration of the epididymis may be associated with inflammation and epididymal obstruction. Post-epididymal obstruction of the reproductive tract may result in "fullness" of the epididymis, when examined by an experienced urologist. If clinically indicated, a scrotal ultrasound should be performed to define the intratesticular and paratesticular structures.

The presence of the vasa deferentia should be confirmed by palpation. Vascular engorgement of the spermatic cords should be assessed and the size of varicoceles recorded. Large bilateral varicoceles or a varicocele that does not decompress with the patient supine may suggest a fixed obstruction in the retroperitoneum and should be further evaluated with ultrasonography and possibly computed tomography of the abdomen. Hernias in the inguinal region should also be assessed. Rectal examination should be performed to assess for prostatic irregularities, bogginess, or tenderness. If clinically indicated, a transrectal ultrasound examination should be performed to evaluate the prostate, seminal vesicles, and ejaculatory ducts. Routine digital rectal assessment for masses as well as guaiac testing of stool is also performed.

BASIC TESTS

Urinalysis

Urinalysis can detect urinary tract infections, retrograde ejaculation, and medical renal disease all of which can impair fertility. The urinalysis should include a dip stick analysis of leukocytes, pH, protein, glucose, ketones, blood, and hemoglobin. Routinely, after a semen specimen a post ejaculate urine (PEU) is given. The entire contents of the bladder should be evacuated, the volume measured and concentrated, if too large a volume is obtained. The total number of sperm in the specimen is determined. The spun specimen should be evaluated microscopically (preferably by phase contrast microscopy) and the number of sperm, round cells, bacteria, and crystals quantified. Chlamydia is a common pathogen that impairs both female and male fertility. Simplified kits for evaluation of Chlamydia in a voided urine specimen (Kodak SureCell) are readily available and easily incorporated into the routine evaluation.

Semen Analysis

Semen analysis is usually the first test performed in male factor evaluation. A detailed presentation was given in a companion *AUA Update Series*.⁸ Several key points will be summarized here. Multiple analyses separated by three to four week intervals are important to adequately evaluate fertility potential. It is important to provide patients with clearly *written* instructions on how to produce a specimen and as to the type of container to use. Routinely we ask for 48 to 72 hours of abstinence. When the specimen is received in the laboratory, it is placed in an incubator at 37°C. We note the time of collection, the time that we evaluate it and whether it is a complete sample or whether some loss occurred during collection. We also ask for a post-ejaculate urine to be given at this time.

The physical characteristics such as liquefaction, viscosity, volume, color, and pH are noted and recorded. A microscopic examination is then performed. The parameters recorded are

MORPHOLOGY

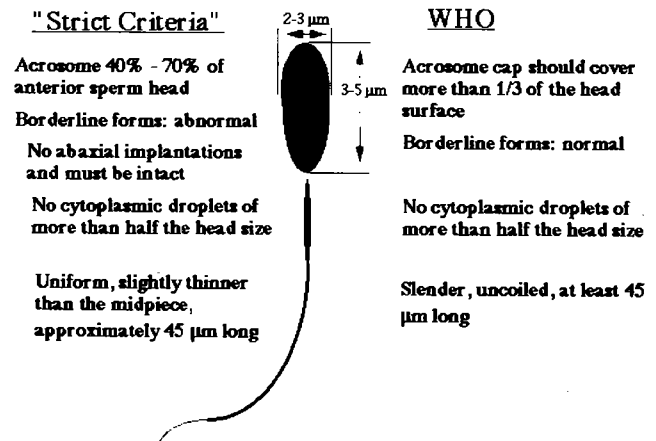


Figure 1

Several of the key differences between the "strict criteria" and WHO criteria are shown. Using the "strict criteria" the acrosome must be 40 to 70 percent of the sperm head. Borderline forms are considered abnormal.

concentration, total sperm count, motility and forward progression, and morphology. **If no sperm are seen, and/or the volume is less than 1.5ml, a fructose test should be done to confirm the presence of seminal vesicle fluid, as well as a post ejaculate urine, to rule out retrograde ejaculation.** If motility is less than 50 percent, a **viability** stain is done using Eosin Y with Nigrosin as a counterstain. Greater than 50 percent of the sperm should be viable (i.e., non-stained). Morphology is the most subjective parameter measured in the semen analysis. Sperm have a head, a mid-piece and a tail, each component of which has particular morphologic characteristics. Figure 1 shows a comparison between the strict morphologic criteria of Kruger et al⁹ and that of the WHO.¹⁰ The head of the normal human spermatozoa is ovoid in the frontal view and pyriform in the lateral view. Fixed and stained (Papanicolaou) sperm heads measure approximately 3 to 5 microns in length and 2 to 3 microns in width. The acrosome should make up somewhere between 40 to 70 percent of the normal sperm head. The mid-piece has a mitochondrial sheath and often excess cytoplasmic material from the developing spermatid. The tail principal piece is approximately 50 to 55 micra in length and varies in thickness from about 1 micron near the base to 0.1 microns at the tip of the end-piece as shown by electron microscopy. The tail is composed of an axial core consisting of two central singlet microtubules surrounded by nine pairs of doublet microtubules, an outer ring of nine dense fibers surrounded by the fibrous sheath which define the principal piece of the tail. Menkveld et al¹¹ have described an association between the "strict" morphologic evaluation of spermatozoa and the results of *in vitro* fertilization. Of particular note is the direct relationship between acrosome size and the frequency of both pregnancy and fertilization.

Hormonal Studies

An appropriate hormonal milieu must exist for the reproductive organs to produce, mature, and transport the highly specialized male gamete to the ejaculatory duct. The entire system of hormone balance is initiated by the pulsatile hypothalamic release of Gonadotropin releasing hormone (GnRH). Pituitary LH secretion is determined by GnRH pulses from the hypothalamus, that occur approximately every two hours and

are carried via a venous portal network to the pituitary. This hypothalamo-hypophyseal portal connection allows an exact synchrony of GnRH and LH pulse secretion. FSH secretion is also stimulated by GnRH, but FSH and LH are differentially regulated by hormonal and other factors that are poorly understood. The factors influencing FSH secretion are produced by Sertoli cells and other components of the testis that probably includes peptides of the inhibin and activin families. Within the testis, LH stimulates Leydig cell synthesis of testosterone.

Testosterone production by the Leydig cell provides locally high intratesticular concentrations of this hormone that stimulates spermatogenesis. Testosterone concentrations in peripheral blood of men change dramatically during the life cycle. Testosterone reaches a maximum concentration during the second or third decade of life, then reaches a plateau, and declines thereafter. Additionally, annual and daily rhythms in testosterone concentration occur, typically with a testosterone peak in the early morning. Other, irregular fluctuations in testosterone concentration may also be detectable in peripheral blood. Testosterone is normally aromatized in peripheral tissue to estrogens. Excessive testosterone levels, associated with gonadotropin, clomiphene citrate or flutamide treatment, may paradoxically result in increased feminization from conversion of androgens to estrogens by aromatase. Similarly, increased aromatase activity is associated with alcoholism and chronic liver disease, as well as testis tumors.

Accurate clinical assessment of the pituitary gonadotropins LH and FSH must take into account their pulsatile release. During clinical research studies, three serum samples are obtained, one every 30 minutes, and the sera pooled for accurate determination of mean gonadotropin levels. This process is usually not necessary in clinical practice, but the clinician should be aware of the potential for LH and FSH peaks to be measured in a single gonadotropin determination, and perform repeat evaluation if LH and FSH hormone levels are both elevated. Testosterone levels may be decreased in the late afternoon or evening. Interpretation of serum testosterone levels should take the diurnal secretion of this hormone into account. Prolactin, another pituitary hormone, may affect fertility by decreasing LH production, resulting in a decrease in testosterone and subsequently, decreased libido. The release of prolactin is mediated by dopamine, and the dopamine antagonist bromocriptine will ameliorate the antifertility effects of hyperprolactinemia.

Testosterone is converted intracellularly within most androgen sensitive organs to dihydrotestosterone. Function of the prostate, seminal vesicles, vasa deferentia, and other sex accessory organs are all androgen dependent. The degree to which partial androgen deprivation in the hypogonadal man affects the function of these organs is unknown. Furthermore, the effects of "low-normal" serum testosterone levels on these organs and a man's fertility potential are unknown.

In summary, knowledge of the hypothalamic-pituitary gonadal axis is important in evaluation of the subfertile male. Our routine blood studies therefore include testosterone, FSH, LH, prolactin, and estradiol.

Ultrasound Evaluation

Ultrasound evaluation of the genitourinary system is rapidly becoming the "urologist's stethoscope." In male factor subfertility the ability to evaluate the paratesticular structures, the region of the ejaculatory ducts and retroperitoneum has made possible the diagnosis of various conditions previously only able to be diagnosed by invasive procedures. For example, the presence of utricle or ejaculatory duct cysts and/or seminal vesicle

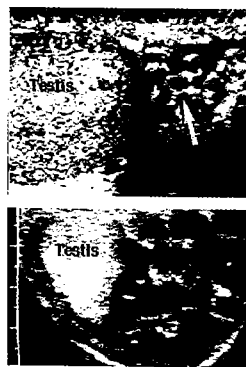


Figure 2

Transverse scrotal ultrasound image of small (upper image) and large (lower image) dilated veins posterior to the testis. Color flow Doppler ultrasound would demonstrate retrograde blood flow in these dilated veins with valsalva.

obstruction can be readily visualized by transrectal ultrasound. This would allow transurethral resection to be performed without the need for a vasotomy and vasogram. In addition, the identification of epididymal obstruction, documentation of varicoceles both before and after repair, evaluation of testicular parenchyma in the presence of a hydrocele and accurate measurement of testicular size aid greatly in our understanding of the pathology which, in turn, allows a more precise therapeutic intervention.

Standards and Guidelines for the performance of the various ultrasound examinations have been published. These can be obtained through the American Institute of Ultrasound in Medicine (AIUM, Executive Office, 4405 East-West Highway, Suite 504, Bethesda, Maryland 20814).

Scrotal Ultrasound Examination

Ultrasound scanning of the scrotum has continued to be a mainstay in the evaluation of both acute and chronic scrotal lesions. Through the use of high resolution and high frequency (7.5 to 10 MHz) images, both testicular and paratesticular structures can be evaluated. In the evaluation of the subfertile male, testicular size can be objectively assessed and followed through therapy. Also the presence (and resolution) of varicoceles can be documented. Other uses of scrotal ultrasonography include: evaluation of scrotal masses (testicular versus extratesticular, cystic versus solid), evaluation of hydrocele, evaluation of the acute scrotum (particularly color flow Doppler), and evaluation of the traumatized scrotum.^{12,13}

Indications for scrotal ultrasound in male factor subfertility include: 1) palpable epididymal or testicular masses; 2) testicular pain; 3) thickened scrotal skin—making clinical exam difficult or imprecise; and 4) significant titers of antisperm antibody. Scrotal ultrasound is also useful in measuring the size of the testes as well as documenting the resolution of varicoceles postoperatively. With the increased incidence of carcinoma-in-situ found in the subfertile male,¹⁴ scrotal ultrasound can also provide documentation of the intratesticular echogenicity. This is particularly important in subfertile men with atrophic testes.

Doppler/Color Flow Studies

Hand held Doppler devices have been found to be valuable in assessing arterial flow to a wide variety of organ systems. In reproductive urology they have been successfully utilized as an aid in the evaluation of retrograde venous flow. When evaluation of the scrotum is difficult secondary to thickened scrotal skin or a thickened cord, the use of a hand held Doppler can confirm the presence of varicoceles. However, hand held Doppler units are associated with a high false positive detection rate and are not as specific as color Doppler ultrasound.

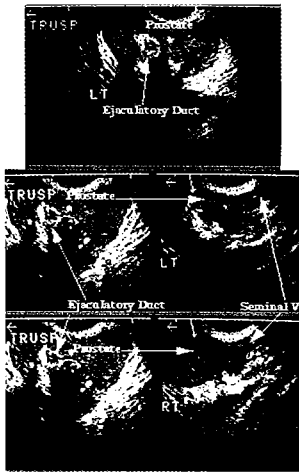


Figure 3

Transrectal ultrasound of a 44-year-old patient with a 17 year history of secondary subfertility. He developed hematospermia two years after treatment for prostatitis. His ejaculate volume was 0.7 ml with 110 million sperm per ml, 60 percent with good forward progression and 50 percent with normal morphology. Fifty percent of his sperm had head bound antisperm antibody. The top panel shows a transverse image of

the prostate while the middle and lower panels show a transverse image on the left and an axial image on the right. Note the increased echogenicity at the level of the ejaculatory duct particularly on the left and the decreased echogenicity of the seminal vesicle. These findings are consistent with partial obstruction.

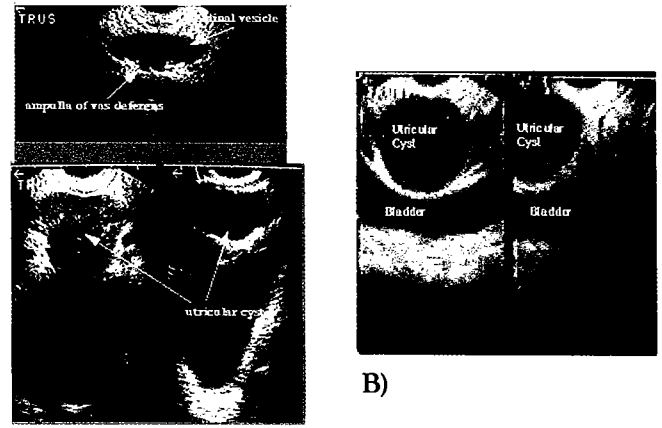
Color flow imaging requires specialized ultrasound equipment capable of representing flow velocity as a color superimposed on the real time gray scale image. Although color flow imaging is useful in evaluating arterial inflow, its greatest value in male factor evaluation is in differentiating varicoceles from dilated epididymal tubules and documenting retrograde flow in varicoceles. Criteria for the diagnosis of varicocele has been evolving. There is presently no "gold standard" for the diagnosis of varicocele. We consider varicoceles to be small if less than 3 mm in maximal diameter, moderate if 3 to 6 mm in maximal diameter and large if greater than 6 mm in maximal diameter. These measurements are made on veins with retrograde flow localized posterior to the testis during valsalva (Figure 2).

The term "subclinical" varicocele has been used to describe a varicocele found on ultrasound examination but not able to be found by palpation. A "subclinical" varicocele is not necessarily "small" when measured by ultrasound as described above. The use of color flow imaging yields information regarding the size, location, and characteristics of varicoceles. These measurements are objective. They are not affected by the patients' physical characteristics (e.g., obesity, scrotal skin thickness, cord size, or testicular size). At present color flow imaging is the most precise method we have available for characterizing a varicocele.

Transrectal Ultrasound Examination (TRUS)

The use of high resolution and high frequency (5 to 7 MHz) transducers has allowed superb imaging of the prostate, seminal vesicles, and ejaculatory ducts. The advantages of TRUS over other imaging modalities (CT scan, MRI, vasography) include better resolution, its relatively non-invasive nature and lower cost. In evaluating the subfertile male TRUS has become increasingly important.¹⁵⁻¹⁷

Indications for TRUS in evaluating the subfertile male include: 1) azoospermia; 2) abnormal digital rectal examination; 3) retrograde ejaculation; 4) suspicion of partial obstruction (volume <1.5ml, motility <10 percent or a forward progression <2 (3 to 4 is normal), less than 20 percent normal forms, pyospermia or hematospermia); and 5) hematospermia or pyospermia (Figure 3). In the azoospermic patient, seminal vesicle and ejaculatory duct obstruction can be



A)

Figure 4

A) Transverse and axial views of the prostate and seminal vesicles in a 32-year-old male with a 0.8 cc ejaculate volume (fructose positive). Note the large midline utricular cyst extending from the level of the veru to the seminal vesicle. No dilation of the seminal vesicle or ampulla of the vas deferens is seen (upper view). **B)** 43-year-old cardiologist with a ten year history of a low (1.0 to 1.8 cc) ejaculate volume and perineal discomfort. Note the large utricular cyst without evidence of seminal vessel dilation.

documented. In the patient with a low ejaculate volume, partial obstruction of the ejaculatory duct can be diagnosed as well as abnormalities of the seminal vesicles (Figures 4A and 4B). Also in patients with pyospermia, the characteristic findings associated with acute and chronic prostatic infections can be assessed (Figure 3).

Renal Ultrasound Examination

Abdominal ultrasound, with particular emphasis on the kidneys and retroperitoneum, is occasionally important in the evaluation of the subfertile male. Patients with a non-palpable vas deferens often have concomitant congenital abnormalities of the ipsilateral seminal vesicle and 20 percent are missing the ipsilateral kidney. In addition, the presence of a large right varicocele or any large varicoceles that don't collapse in the supine position require evaluation of the retroperitoneum for masses.

Devices for Recording Scrotal Temperature

Maintenance of normal differentials between intratesticular and intra-abdominal temperatures is essential for normal spermatogenesis. Animal studies have successfully employed fine gauged needle thermistors for accurately recording intratesticular temperatures. The limitations of such techniques for human infertility investigations are obvious. Clinical investigators have however employed surface probes and thermographic recording devices for measuring scrotal temperatures. The premise upon which the usefulness of these devices depends however is that scrotal surface temperature is somehow a reflection of intratesticular temperature. In fact there is little reason to suspect that surface scrotal temperature would accurately reflect intratesticular temperatures. The blood flow and nerve supply to the scrotum and testis are entirely separate. Furthermore, scrotal temperature likely varies in response to external temperature changes thus maintaining constant intratesticular temperatures. We have attempted to shed some light on this issue by measuring intratesticular and scrotal surface temperatures

using a sensitive needle thermistor during the course of scrotal procedures performed under general anesthesia. We have found a very good correlation between scrotal surface temperatures and intratesticular temperatures in anesthetized patients.¹⁸ However, the clinical usefulness of devices measuring scrotal surface temperature in ambulatory patients has not been well-defined.

CT-Scan and MRI

Computerized Axial Tomography (CT scan) is occasionally useful in infertility evaluation in men with suspected aplasia or absence of the seminal vesicles. CT scan examinations of men with non-palpable vasa detected the presence of at least aplastic seminal vesicles in half such men. There is much potential for Magnetic Resonance Imaging (MRI) to advance the diagnosis of male factor subfertility. In addition to its potential ability to resolve the fine structure of the ejaculatory duct vas deferens and epididymis, it is possible that MRI might detect metabolic disorders of testicular function. The wider availability of these powerful devices will allow the accumulation of sufficient experience to answer these questions.

SPECIALIZED TESTS

Antisperm Antibody Tests

Antisperm antibodies are found in about 10 to 15 percent of infertile men. Immunity only to those antigens present on the surface of viable, motile sperm will impair fertility. Antibodies to internal sperm antigens, due to an immune response to sperm degraded in the genital tract or to cross-reacting microbial antibodies present in the sera of many fertile individuals, are of questionable relevance to infertility.

Antisperm antibodies can be found in serum (i.e. circulating), seminal fluid, and bound to sperm. Initially, it was thought that circulating antisperm antibodies were representative of those bound to the sperm surface. However, numerous investigators have found that antisperm antibodies are bound to sperm in only 30 to 50 percent of the cases in which antibodies are found in the serum. In addition, when both are present, the antibody classes may be different in each case. Therefore, clinical analysis for antisperm antibodies must include detection of antibody bound to the surface of sperm. Ideally, the test should also delineate the site at which the antibody is bound.

Antibodies bound to sperm and not circulating antisperm antibodies are most likely responsible for the impaired semen analysis and adverse effects on pregnancy. When testing for the presence of antibody, the most clinically useful tests should be able to identify the presence of antibody bound to the head, midpiece, or tail of motile spermatozoa. Nonmotile or nonviable spermatozoa might have internal membrane antigens exposed yielding false positive results. The two tests presently available that meet this criteria are the immunobead binding assay and the SpermMar assay.

The presence of agglutination on semen analysis has often been assumed to represent the presence of sperm bound antibody. Often nonimmunological causes have been found to be present when agglutination is found. However, when a specimen has a number of sperm moving in pairs, attached either at the head or tail (called dimers), we have found this phenomena to be pathognomonic for the presence of antibody. Other indications for antisperm antibody testing include an abnormal postcoital test, idiopathic infertility, and factors associated with an increased risk of antibodies. These increased risk factors include vasectomy, infection, obstruction, cryptorchidism, varicocele, testicular biopsy, trauma, torsion, cancer, and a genetic predisposition.

There are several methods to test for antisperm antibodies. These were covered at length in an earlier *AUA Update Series*.⁸

Tests of Sperm Function

Although spermatozoa may look normal, move with good forward progression, and lack surface antibodies, this is no assurance that they perform properly. Of the many tests of sperm function available, none unequivocally identify functional spermatozoa. These tests do not need to be applied for a general evaluation of the subfertile man, but they may be invaluable for selected patients. The various tests available for evaluating sperm function in vitro have recently been superbly reviewed by Liu and Baker.¹⁹

Summary

Advancements in technology and our understanding of reproductive biology has allowed us as clinical urologists to better evaluate and effectively treat an increasing number of men with reproductive disorders. However, this is only the beginning of what promises to be an exciting and rapidly expanding area of clinical urology.

REFERENCES

- Schlegel PN, Berkeley AS, Goldstein M, et al: Epididymal micropuncture with IVF for treatment of surgically unreconstructable vasal obstruction. American Fertility Society Convention 1992.
- Patrizio P, Silber S, Ord T, et al: Two births after microsurgical sperm aspiration in congenital absence of vas deferens—letter. *Lancet* 1988; 2(8624):1364.
- Gorelick J, Goldstein M: Loss of fertility in men with varicoceles. *Fert Steril* 1992; In press.
- Witt M, Lipshultz L: Varicocele—A progressive or static lesion? AUA Annual Meeting, Toronto, Canada, 1991.
- Schlegel P, Chang T: The testis, epididymis and ductus deferens, in Walsh P, Retik A, Stamey T, Vaughan E, (eds): *Campbell's Urology*. Philadelphia, WB Saunders, 1992, vol 1, pp 190-200.
- Mieusset R, Bujan L, Mondinat C, et al: Association of scrotal hyperthermia with impaired spermatogenesis in infertile men. *Fert Steril* 1987; 48(6):1006-1011.
- Goldstein M: Evaluation of the infertile male. *AUA Update Series* 1984; 3(22):1-8.
- Gilbert BR, Cooper GC, Goldstein M: Semen analysis in the evaluation of male factor subfertility. *AUA Update Series* 1992; 11(32):250-255.
- Kruger T, Acosta A, Simmons K, et al: Predictive value of abnormal sperm morphology in in vitro fertilization. *Fertil Steril* 1988; 49:112.
- WHO. WHO Laboratory manual for the Examination of Human Semen and Semen-Cervical Mucous Interaction. Cambridge, University Press, 1987.
- Menkveld R, Oettle TF K, Acosta A, et al: *Atlas of Human Sperm Morphology*. Baltimore, Williams and Wilkins, 1991.
- Patel PJ, Pareek SS: Scrotal ultrasound in male infertility. *Eur Urol* 1989; 16(6):423-425.
- Nashan D, Behre HM, Grunert JH, et al: Diagnostic value of scrotal sonography in infertile men: Report on 658 cases. *Andrologia* 1990; 22(5):387-395.
- Giwerzman A, Berthelsen J, Muller J, et al: Screening for carcinoma-in-situ of the testis. *Int J Androl* 1987; 10:173.
- Worischek J, Mehan D, Parra R: Transrectal ultrasound in the evaluation of men with low volume azoospermia. AUA Annual Meeting, Washington, DC, 1992.
- Wessels E, Ohori M, Grantmyre J, et al: The prevalence of cystic dilation of the ejaculatory ducts detected by transrectal ultrasound (TRUS) in a self-referred (screening) group of men. AUA Annual Meeting, Washington, DC, 1992.
- Patterson L, Jarow JP: Transrectal ultrasonography in the evaluation of the infertile man: A report of 3 cases. *J Urol* 1990; 144(6):1469-1471.
- Goldstein M, Eid JF: Elevation of intratesticular and scrotal skin surface temperature in men with varicocele. *J Urol* 1989; 142(Sept):743-745.
- Liu D, Baker H: Tests of human sperm function in vitro. *Fertil Steril* 1992; 58:465-483.

1. Male factor subfertility is the primary or contributing cause of subfertility in approximately what percentage of couples presenting for a fertility evaluation?
 - a) less than ten percent
 - b) 10 to 30 percent
 - c) 40 to 60 percent
 - d) 70 to 90 percent
 - e) 100 percent
2. A semen analysis is considered normal when:
 - a) World Health Organization (WHO) criteria are met.
 - b) the couple has conceived a child.
 - c) the sperm penetration assay (SPA) is normal.
 - d) semen parameters are normal and the couple conceives a child.
 - e) sperm count is over 50 million/ml.
3. With today's technology, a male should be considered to be fertile as long as:
 - a) a testis is present.
 - b) the genotype is 46xy.
 - c) the wife has no tubal obstruction.
 - d) sperm are present at the level of the rete testis/efferent ductules.
 - e) the seminal fructose is normal.
4. Approximately what percent of men with secondary subfertility have been found to have varicoceles?
 - a) 20 percent
 - b) 40 percent
 - c) 60 percent
 - d) 80 percent
 - e) 100 percent
5. Measurement of testicular volume is important in evaluation of the subfertile male because:
 - a) testicular size correlates with fertility potential.
 - b) testicular size correlates with testosterone level.
 - c) testicular size correlates with spermatogenic potential.
 - d) testicular volume correlates with sperm morphology.
 - e) the testis on the side of the varicocele is smaller.
6. Routine hormonal evaluation of male subfertility might include:
 - a) LH, FSH, testosterone, GnRH, estradiol.
 - b) LH, FSH, testosterone, ACTH.
 - c) LH, FSH, testosterone, prolactin, estradiol.
 - d) LH, FSH, testosterone, prolactin, TSH.
 - e) LH, FSH, testosterone, prolactin, ACTH.
7. In fertility evaluation, scrotal ultrasound can be useful in all except:
 - a) determining testicular size.
 - b) identifying an obstructed epididymis.
 - c) documentation of varicoceles.
 - d) evaluation of testicular function.
 - e) diagnosis of a palpable epididymal or testicular mass.
8. Transrectal ultrasound (TRUS) can be useful in evaluation of all except:
 - a) teratozoospermia.
 - b) ejaculatory duct obstruction.
 - c) pyospermia.
 - d) azoospermia.
 - e) a low volume ejaculate.
9. Antisperm antibodies of clinical importance:
 - a) are tail bound.
 - b) are surface bound.
 - c) are present in serum.
 - d) prevent sperm motility.
 - e) cause sperm caput loss.
10. A definitive diagnosis of hypogonadotropic hypogonadism requires:
 - a) lack of secondary sexual characteristics.
 - b) presence of long arms.
 - c) short fourth metacarpals.
 - d) gynecomastia.
 - e) serum hormonal evaluation.