

## PERCUTANEOUS TESTIS BIOPSY: AN ALTERNATIVE TO OPEN TESTICULAR BIOPSY IN THE EVALUATION OF THE SUBFERTILE MAN

THOMAS G. HARRINGTON, DONALD SCHAUER AND BRUCE R. GILBERT

*From the Department of Urology, State University of New York at Stony Brook, Stony Brook, New York*

### ABSTRACT

**Purpose:** We evaluated the safety and efficacy of percutaneous testis biopsy by comparing the ultrasound appearance and histological status of testicular parenchyma obtained to those noted after open testis biopsy.

**Materials and Methods:** A total of 51 consecutive infertile men with azoospermia or severely impaired semen quality, in whom ductal obstruction was suspected, underwent percutaneous (31) or open (20) testis biopsy, with 58 and 34 procedures performed, respectively. Scrotal ultrasound was performed preoperatively, and at 2 weeks and 1, 3 and 6 months after biopsy. In addition, immunoglobulins G and A antisperm antibody assays were obtained preoperatively and postoperatively. Two biopsy specimens were obtained from each testis for formal histological evaluation. A touch preparation was also performed and examined immediately for mature spermatozoa using phase contrast microscopy.

**Results:** All biopsies yielded adequate tissue for diagnosis and morphometric analysis. Of 58 percutaneous biopsies 4 (7%) demonstrated sonographic evidence of intratesticular bleeding, characterized by a hypochoic region within the testicular parenchyma, which resolved by 6 months postoperatively. In contrast, 10 of 34 open biopsies (29%) showed evidence of intratesticular bleeding or a new area of increased echogenicity at 1 month after the procedure (intraparenchymatous scar). All intraparenchymatous scars persisted to 6 months postoperatively. No patient undergoing percutaneous or open testis biopsy had antisperm antibodies in the seminal fluid or serum (azoospermia cases) or on sperm postoperatively. Of the 32 and 20 patients undergoing percutaneous and open testis biopsy 3 (9%) and 14 (70%), respectively, required narcotic analgesia. All patients returned to routine activities within 24 hours after percutaneous testis biopsy. No postoperative infections or extratesticular hematomas were noted. Pathological study was diagnostic in all specimens.

**Conclusions:** Percutaneous testis biopsy is well tolerated by the patient, with fewer apparent complications than and diagnostic value equal to open testis biopsy. Percutaneous testis biopsy should be considered an alternative to open biopsy.

**KEY WORDS:** testis; biopsy; scrotum; ultrasonography; infertility, male

Testis biopsy is an integral part of the evaluation of the subfertile man presenting with azoospermia or severe oligospermia. In the past open testis biopsy has been the standard procedure to obtain testicular tissue for histopathological examination. Recent studies have suggested that a percutaneous testis biopsy performed in the office yields adequate diagnostic tissue with minimal patient discomfort and much less cost.<sup>1-3</sup>

Concerns have been raised regarding the potential complications of percutaneous biopsy, including inability to obtain diagnostic tissue, pain and potential for infections. Percutaneous testis biopsy is a relatively simple procedure that can be performed with local anesthesia in the office. To examine these issues we evaluated men undergoing in office percutaneous testis biopsy and a cohort undergoing open testis biopsy to compare the intratesticular ultrasound appearance before and after the procedure, and biopsy findings. In addition, patient acceptance of the procedure and need for postoperative analgesia also were discussed.

### METHODS

A total of 51 consecutive subfertile men with azoospermia or severe oligospermia (sperm concentration less than  $5.0 \times 10^6/\text{ml}$ .)<sup>4</sup> underwent percutaneous (31) or open (20) testis biopsies. There were 58 (27 bilateral and 4 unilateral) and 34 (14 bilateral and 6 unilateral) procedures performed, respectively. Open biopsies were performed with general anesthesia via a well described standard technique,<sup>4</sup> and were often followed by a definitive procedure for treatment of infertility (for example, microsurgical ductal reconstruction).

Percutaneous testis biopsies were performed in the office. Blood pressure, pulse oximetry and electrocardiography were monitored in all patients during the procedure. The patient was placed supine on the procedure table, and the scrotum was prepared and draped in the usual sterile fashion. With the surgeon on the right side of the patient 2% lidocaine hydrochloride was injected subcutaneously along the median raphe and skin overlying the lateral aspect of the right testis, raising a small wheal as described by Li et al (fig. 1, A).<sup>5</sup> Lidocaine hydrochloride was also infiltrated through the median raphe around the vas deferens bilaterally in 26 of the 31 patients using a 25 gauge, 1.5-inch needle. The epididymis of each testis was grasped between the thumb and forefinger

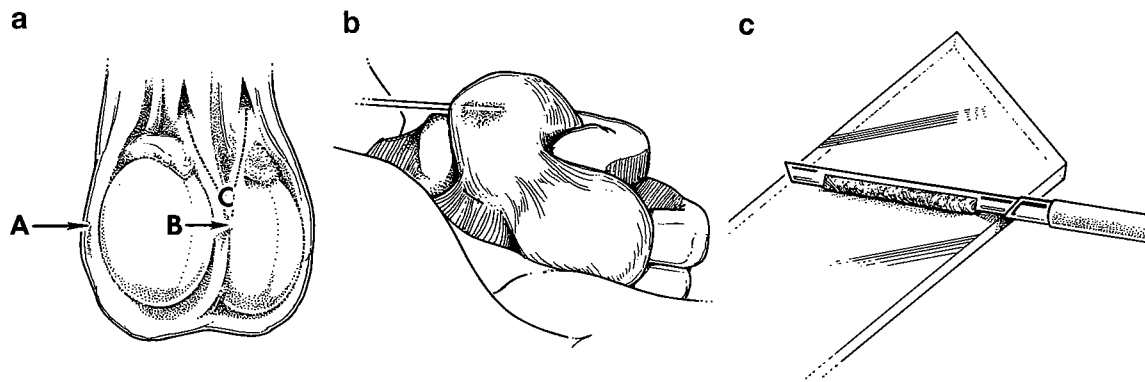


FIG. 1. *a*, for local anesthesia 2% lidocaine is infiltrated in skin on lateral aspect of right testis (A) and along median raphe (B). Additional lidocaine is infiltrated through median raphe along right and left vasa deferentia (C). *b*, holding right testis with scrotal skin held taut, thumb and index finger grasp epididymis with testis elevated above level of fingers to prevent accidental injury to epididymis. Note that index finger is lower than trajectory of biopsy needle to prevent injury to surgeon. *c*, for touch preparation, specimen in notch on tip of biopsy needle is rolled onto sterile slide. Drop of phosphate buffered saline is added and cover slip is placed.

of the nondominant hand, and held posteriorly to stabilize the testis and prevent epididymal injury (fig. 1, *B*). While the testis was displaced anteriorly 2 small skin incisions were made at the biopsy sites with a No. 11 blade to prevent inclusion of skin in the specimens.

An 18 gauge, 15 cm. long Microvasive\* biopsy needle system with a specimen notch 17 mm. long and 1 mm. deep was used to obtain 2 biopsy specimens from each testis. With gentle pressure the tip of the biopsy needle was touched to the tunica albuginea of the testis in a mediolateral (left testis) or lateral-medial (right testis) direction, and the trigger was depressed. One biopsy specimen was touched to a sterile slide (fig. 1, *C*), mixed with a drop of Dulbecco's phosphate buffered saline, and examined immediately with a phase contrast microscope at 200 $\times$  and 400 $\times$  magnification for mature spermatozoa (fig. 2). The cores were rolled onto a 0.5 cm. sheet of sterile specimen paper and placed immediately into Bouin's solution in preparation for formal sectioning. Pressure was applied to each biopsy site to stop any scrotal skin bleeding and prevent intraparenchymatous hematoma formation.

All slides were reviewed by 3 independent observers, and evaluated for mean number of seminiferous tubular cross sections, mean tubule diameter, spermatid count, Johnsen and Agger score,<sup>6,7</sup> and degree of hyalinization. To determine the mean number of seminiferous tubular cross sections the tissue obtained from biopsy was placed in Bouin's solution, embedded in paraffin, stained and sectioned. Multiple sections were mounted on a glass slide. The number of seminiferous tubule cross sections per biopsy section was counted from a minimum of 10 sections and mean number of cross

sections of seminiferous tubules per biopsy section was calculated.

Scrotal ultrasound was performed using a linear 7.5 mHz. probe preoperatively, and within 30 minutes (only for the percutaneous testis biopsy group), at 2 weeks, and at 1, 3 and 6 months postoperatively. Antisperm antibodies were measured preoperatively, and at 3 and 6 months after the procedure. Any positive tests (greater than 10% binding to head, midpiece or tail) were confirmed by immunobead binding studies.<sup>8</sup> Statistical analysis was performed with computer software.

#### RESULTS

Lidocaine was not infiltrated into the spermatic cord in the first 10 patients.<sup>2</sup> Of these patients 2 exhibited vasovagal responses with transient bradycardia, hypotension and diaphoresis. With addition of a spermatic cord block none of the subsequent 21 patients showed similar effects. Four of 31 patients (13%) who underwent percutaneous testis biopsy (4 of 58 biopsies, 7%) demonstrated sonographic evidence of intratesticular bleeding characterized by a hypochoic region in the testicular parenchyma within 30 minutes after the procedure (fig. 3, *A*): 2 cases resolved by 3 months (fig. 3, *B*) and 2 by 6 months postoperatively. Of these patients 2 reported use of a nonsteroidal anti-inflammatory drug within 1 week preoperatively. In contrast, 10 of 20 patients (50%) who underwent open testis biopsy (10 of 34 biopsies, 29%) showed intratesticular bleeding or a new area of increased echogenicity at 1 month postoperatively, consistent with an intraparenchymatous scar (fig. 4). All intraparenchymatous scars persisted 6 months postoperatively.

Of 20 patients undergoing open testis biopsy 14 (70%) requested narcotic analgesia for 2 days or longer postopera-

\* Microvasive Corp., Watertown, Massachusetts.

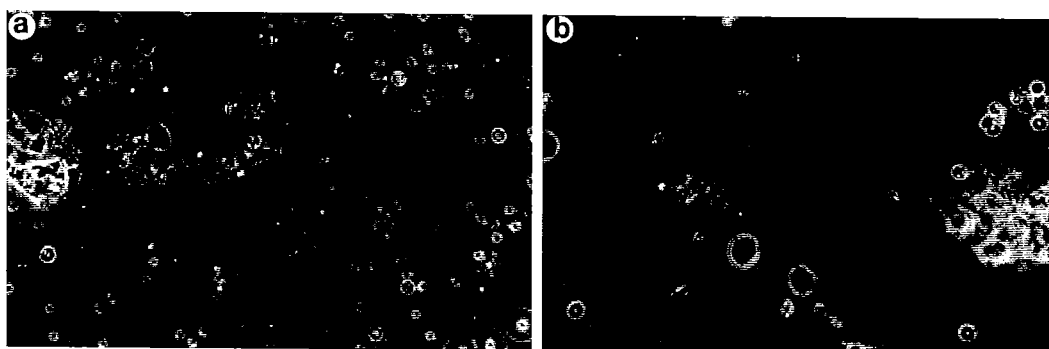


FIG. 2. Wet preparations from percutaneous testis biopsy. *a*, reduced from  $\times 200$ . *b*, reduced from  $\times 400$

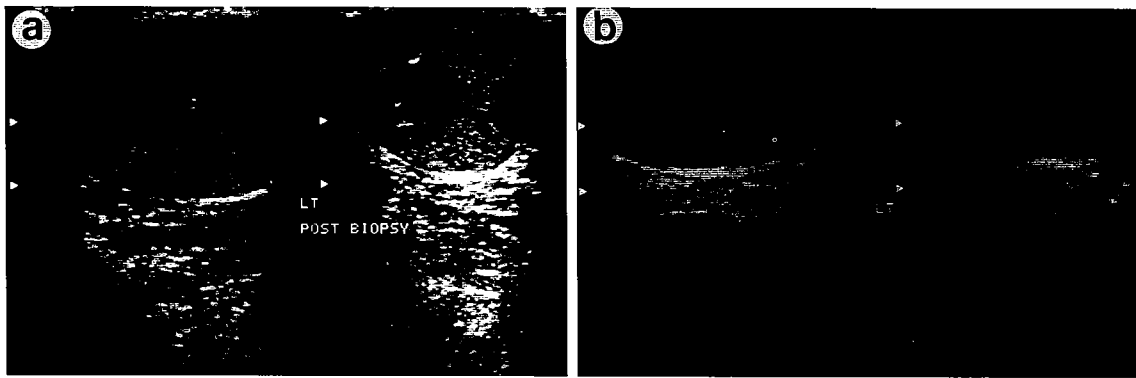


FIG. 3. Ultrasound appearance of testis 30 minutes after percutaneous testis biopsy (a) and 2 weeks later (b). LT, left




FIG. 4. Ultrasound appearance of intraparenchymatous scar 3 months after open testis biopsy. LT, left.

tively, compared to 3 of 32 (9%) undergoing percutaneous testis biopsy. The latter 32 patients returned to routine activities within 24 hours. The procedure was limited to unilateral biopsy in 2 of the 3 patients in the percutaneous testis biopsy group in whom no spermatic cord block was performed due to dizziness and/or diaphoresis. Two patients undergoing percutaneous testis biopsy had a solitary testis. In the open testis biopsy group a unilateral procedure was performed due to a solitary testis in 4 patients and a markedly atrophic contralateral testis in 2.

Mean number of cross sections of seminiferous tubules obtained plus or minus standard deviation was  $14.5 \pm 8.0$  for percutaneous and  $100.8 \pm 64.9$  for open testis biopsy ( $p < 0.05$ , table 1). In 23 of the 58 percutaneous biopsy cross sections (40%) less than 10 tubules were noted. Mean number of spermatids per tubule was  $7.2 \pm 8.8$  in the percutaneous compared to  $14.6 \pm 11.1$  in the open testis biopsy groups, and mean tubule diameter was  $130.8 \pm 16.0$  and  $175.1 \pm 31.6$   $\mu\text{m}$ ., respectively. More than 20% binding of immunoglobulins G or A antisperm antibodies preoperatively bound to sperm or in serum was noted in 1 of 20 patients (5%) in the open and 2 of 31 (7%) in the percutaneous testis biopsy groups. No patient had new or increased levels of antisperm antibodies in seminal fluid or serum (for patients with azoospermia) or on sperm when tested 6 months postoperatively.

TABLE 1. Morphological parameters

	Percutaneous Biopsy	Open Biopsy
No. biopsies	58	34
No. tubules $\pm$ SD*	$14.5 \pm 8.0$	$100.8 \pm 64.9$
Johnsen and Agger score $\pm$ SD*, <sup>6,7</sup>	$4.9 \pm 2.8$	$6.6 \pm 2.6$
No. spermatids/tubule $\pm$ SD*	$7.2 \pm 8.8$	$14.6 \pm 11.1$
Mean tubule diameter $\pm$ SD ( $\mu\text{m}$ .)*	$130.8 \pm 16.0$	$175.1 \pm 31.6$
No. hyalinization	$3.3 \pm 0.83$	$2.6 \pm 0.78$

\*  $p < 0.05$ .

#### DISCUSSION

Testis biopsy is a valuable tool in the evaluation of the subfertile man, particularly in determination of ductal obstruction versus primary testicular failure in patients with azoospermia or severe oligospermia. Traditionally, testis biopsy has been performed in patients with normal sized testes and normal or mildly elevated serum follicle-stimulating hormone levels. However, with the advent of micromanipulation techniques the role of testis biopsy has been expanded to include patients with elevated follicle-stimulating hormone and/or small testes, since only a few sperm (or possibly even round spermatids) may be used for micro-insemination. In addition, several investigators have suggested that findings on testis biopsy may have prognostic significance in the treatment of varicoceles,<sup>7,9</sup> as well as surgery for ductal obstruction.<sup>4,10</sup> Despite the enormous value of testis biopsy, concern remains about the percutaneous approach regarding diagnostic accuracy of the biopsy specimen, possibility of injury to valuable spermatogenic tissue or potential for development of antisperm antibodies in the already infertile patient.

The score of Johnsen and Agger,<sup>6,7</sup> spermatids per tubule and tubule diameter were greater with open compared to percutaneous testis biopsy (table 1). Although testis size was not different between the 2 groups (table 2), we were more inclined to perform percutaneous biopsy in a patient with a soft testis before reconstruction. The Johnsen and Agger score represents a quantitative analysis of testis histology in which each tubule is given a number from 10 (complete spermatogenesis) to 1 (no cellular elements present) based on the maturity of the cellular content.<sup>6,7</sup> A mean score is derived by averaging all tubules quantified. In the human testis tissue sampling could conceivably affect the calculated score. Although the lowered value obtained with the percutaneous biopsies could possibly reflect the decreased amount of tissue obtained due to sampling, it more likely represents an increased number of patients with impaired spermatogenesis in this group. This possibility is supported by the findings that 13 of 20 patients (65%) in the open testis biopsy group underwent simultaneous exploration after sperm were found on the touch preparation, while only 9 of 31 (29%) in the percutaneous testis biopsy group underwent subsequent

TABLE 2. Testicular volume

	Testis Biopsy	
	Open	Percutaneous
Lt. testis:		
Mean vol. $\pm$ SD (cc)	$12.9 \pm 5.7$	$11.9 \pm 6.6$
No. biopsies	17	30
Rt. testis:		
Mean vol. $\pm$ SD (cc)	$16.0 \pm 8.4$	$12.6 \pm 6.7$
No. biopsies	17	28

Differences were not statistically significant.

reconstruction. Of note, 8 of 13 patients (62%) undergoing concomitant reconstruction at open testis biopsy had motile sperm at the site of epididymal anastomosis. Among the 5 patients without motile sperm at the anastomosis review of the formal biopsy slides revealed severely impaired spermatogenesis even though the touch preparation demonstrated spermatozoa. Thus, an additional benefit of percutaneous testis biopsy is the ability to review the biopsy slides before surgical intervention to determine whether reconstruction or other options, such as aspiration or testicular sperm retrieval, would be best. It should be noted that 57% of our patients undergoing biopsy did not undergo subsequent reconstruction. Therefore, in the majority of men we could avoid anesthesia, operating room costs and risks by initially performing in office percutaneous testis biopsy.

In the past open testis biopsy has been considered the standard procedure to obtain testis tissue for histopathological examination. Its reliability in pathological diagnosis has been well documented, as is the ability to ensure hemostasis during the procedure. However, this procedure incurs many inconveniences for the patient (that is preoperative testing and hospitalization) and often requires an anesthesiologist, which increases the cost of the procedure. Although local anesthesia has been used for open testis biopsy, this procedure often is uncomfortable and poorly tolerated by patients.<sup>9</sup> The increased cost of open testis biopsy compared to an office procedure is approximately \$3,000 due to the need for an anesthesiologist (\$600), costs associated with preoperative testing (\$400), and use of the ambulatory unit, and operating and recovery rooms (\$2,000). These figures represent mean charges billed by 3 local outpatient surgical facilities and assume a bilateral procedure, billed at the minimal time of 1 hour in the ambulatory surgery unit, and operating room and recovery rooms.

In recent years several studies have supported use of testicular fine needle aspiration as an alternative to open testis biopsy for infertility evaluation.<sup>11-13</sup> Fine needle aspiration is an in office procedure that requires only local anesthesia and generally is well tolerated. However, the value of fine needle aspiration is limited by the availability of flow cytometry and/or experience of an examining cytopathologist. In addition, its inability to provide information regarding tubular architecture remains a serious drawback. Also, this technique requires negative pressure to be applied to the testicular parenchyma to obtain tissue, which may cause greater parenchymal bleeding than percutaneous testis biopsy.

Recent reports have described the technique of percutaneous testis biopsy.<sup>1-4</sup> Included among the criticisms of this procedure has been the potential for inadvertent and undetected vascular or epididymal injury due to its blinded nature. In an examination of intratesticular anatomy Jarow demonstrated that the medial and lateral aspects of the upper pole of the testis are less likely to contain major arterial branches of the testicular artery than are the other regions.<sup>14</sup> Therefore, it is recommended that percutaneous biopsies be performed as close to these areas as possible. Serial scrotal ultrasound before and after biopsies revealed a significant difference in sonographic abnormalities in the 2 groups. Sonographically detected abnormalities appeared to be more transient in nature in the percutaneous testis biopsy group, and occurred only in patients with a recent history of nonsteroidal anti-inflammatory drug use. Intraparenchymatous scar formation was not noted at 6 months after percutaneous testis biopsy. No extratesticular hematomas occurred in either group.

In the initial report of Cohen and Warner biopsy was performed with the needle oriented in an anteroposterior direction, which may cause a greater incidence of epididymal injuries.<sup>1</sup> In our series epididymal injury was avoided by grasping the epididymis with the nondominant hand (fig. 1, B). With the epididymis held posteriorly the testis was sta-

bilized and the long axis of the needle was oriented in a mediolateral direction to prevent injury to the epididymis and surgeon. None of the percutaneous testis biopsy specimens contained epididymal tubules. In addition, 9 of the 31 patients (29%) in this group eventually underwent exploration and none had evidence of injury to the epididymis (as determined by lack of adhesions, hematoma, obvious puncture or disruption of the epididymis). In fact adhesions between the visceral and parietal tunica vaginalis were minimal. The biopsy site appeared only as a brownish spot on the tunica albuginea. Thus, to prevent adhesions in this region (possible for later creation of an epididymal reservoir) percutaneous testis biopsy might be the procedure of choice.

It has been suggested that the lower quantitative yield of spermatogenic tissue obtained with percutaneous compared to open testis biopsy might affect pathological diagnosis. Kessarar et al recently examined this issue and demonstrated a 95% correlation between percutaneous testis biopsy plus touch preparation and open testis biopsy. Although there are fewer cross sections of tubules in a percutaneous than in an open testis biopsy specimen, this did not affect the ability of the pathologist to obtain a diagnosis based on the tissue present. Also, use of a touch preparation may supplement the information provided by percutaneous testis biopsy. Pathological study was diagnostic in all of our percutaneous biopsy specimens.

With use of subcutaneous local anesthesia and spermatic cord block, percutaneous testis biopsy appeared to be well tolerated by the majority of patients. Three patients experienced dizziness and/or diaphoresis, which limited the procedure to unilateral biopsy in 2. However, none of these 3 patients had received a spermatic cord block. Of the 32 patients undergoing percutaneous testis biopsy 3 (9%) required narcotic analgesia for pain relief for several days following biopsy, compared to 12 of 20 (60%) undergoing open testis biopsy. The former 3 patients returned to normal activities within 24 hours after biopsy.

With the growing popularity of micromanipulation techniques (particularly intracytoplasmic sperm injection), methods of sperm and spermatid retrieval have recently achieved new importance. Several recent reports have successfully used percutaneously retrieved testicular sperm for in vitro fertilization via intracytoplasmic sperm injection.<sup>16,17</sup> Therefore, percutaneous testis biopsy may soon be used not only for diagnosis but also treatment of male factor subfertility.

Various conditions, including testis biopsy, have been implicated in the formation of antisperm antibodies, theoretically through violation of the blood-testis barrier.<sup>18</sup> None of our biopsies in both groups resulted in increased antisperm antibodies at up to 6 months postoperatively. All of our patients had azoospermia or severe oligospermia (less than 5 million spermatozoa per cc), making comparison of semen quality before and after biopsy impossible. However, not finding increased antisperm antibodies in serum (or seminal fluid) after biopsy supports the lack of a detrimental effect of testis biopsy on testicular parenchyma.

#### CONCLUSIONS

Our results suggest that percutaneous testis biopsy is a safe, cost-effective and diagnostic procedure that resulted in a lower incidence of sonographically detected injuries and injuries that were transient in nature compared to open testis biopsy. In addition, use of general anesthesia, with its attendant risks, was avoided. Neither percutaneous nor open testis biopsy caused increased antisperm antibodies up to 6 months postoperatively. Percutaneous testis biopsy is easily performed in the office with minimal instrumentation, and it does not require an operating suite or general anesthesia. Although fewer tubules were obtained with percutaneous than with open testis biopsy, the tubular architecture was

preserved and the specimen was diagnostic in all cases. Percutaneous testis biopsy should be considered an alternative to open testis biopsy in evaluation of the subfertile man for whom testis biopsy is indicated.

Dr. Peter N. Schlegel critically reviewed the manuscript and Mr. Thomas A. Brown provided technical assistance.

## REFERENCES

1. Cohen, M. S. and Warner, R. S.: Needle biopsy of testes: a safe outpatient procedure. *Urology*, **29**: 279, 1987.
2. Rajfer, J. and Binder, S.: Use of Biopty gun for transcutaneous testicular biopsies. *J. Urol.*, **142**: 1021, 1989.
3. Morey, A. F., Plymyer, M., Rozanski, T. A., Deshon, G. E., Myers, J. B. and Dresner, M. L.: Biopty gun testis needle biopsy: a preliminary clinical experience. *Brit. J. Urol.*, **74**: 366, 1994.
4. Jow, W. W.: Testis biopsy. In: *Surgery of Male Infertility*. Edited by M. Goldstein. Baltimore: W. B. Saunders Co., chapt. 2, pp. 8-25, 1995.
5. Li, P. S., Li, S. Q., Schlegel, P. N. and Goldstein, M.: External spermatic sheath injection for vasal nerve block. *Urology*, **39**: 173, 1992.
6. Johnsen, S. G.: Testicular biopsy score count—a method for registration of spermiogenesis in human testes: normal values and the results in 335 hypogonadal males. *Hormones*, **1**: 2, 1970.
7. Johnsen, S. G. and Agger, P.: Quantitative evaluation of testicular biopsies before and after operation for varicocele. *Fertil. Steril.*, **29**: 53, 1978.
8. Bronson, R., Cooper, G. and Rosenfeld, D.: Sperm antibodies: their role in infertility. *Fertil. Steril.*, **42**: 171, 1984.
9. Hadziselimovic, F., Leibundgut, B., Da Rugna, D. and Buser, M. W.: The value of testicular biopsy in patients with varicocele. *J. Urol.*, **135**: 707, 1986.
10. Jow, W. W., Steckel, J., Schlegel, P. N., Magid, M. S. and Goldstein, M.: Motile sperm in human testis biopsy specimens. *J. Androl.*, **14**: 194, 1993.
11. Hellstrom, W. J. and Kaack, B.: Optimum testicular aspiration technique for deoxyribonucleic acid flow cytometric analysis of spermatogenesis in primates (*Papio anubis*). *Fertil. Steril.*, **54**: 517, 1990.
12. Chan, S. L., Lipshultz, L. I. and Schwartzendruber, D.: Deoxyribonucleic acid (DNA) flow cytometry: a new modality for quantitative analysis of testicular biopsies. *Fertil. Steril.*, **41**: 485, 1984.
13. Clausen, O. P. and Abyholm, T.: Deoxyribonucleic acid flow cytometry of germ cells in the investigation of male infertility. *Fertil. Steril.*, **34**: 369, 1980.
14. Jarow, J. P.: Intratesticular arterial anatomy. *J. Androl.*, **11**: 255, 1990.
15. Kessar, D. N., Wasserman, P. and Mellinger, B. C.: Histopathological and cytopathological correlations of percutaneous testis biopsy and open testis biopsy in infertile men. *J. Urol.*, **153**: 1151, 1995.
16. Belker, A. M., Sherins, R. J., Coulam, C. B., Opsahl, M. S., Thorsell, L. P., Dorfmann, A. and Schulman, J. D.: High fertilization and pregnancy rates obtained by nonsurgical percutaneous needle aspiration of testicular sperm. *J. Urol.*, part 2, **155**: 364A, abstract 213, 1996.
17. Barnes, F. L., Zouves, C., Rodriguez, H., Botes, A., Miller, F., Chan, S., Sammowitz, H. and Sher, G.: Sperm retrieval from testes biopsy with fertilization and pregnancy following ICSI. San Francisco: Pacific Coast Fertility Society, p. A2, 1996.
18. Hjort, T., Husted, S. and Linnet-Jepsen, P.: The effect of testis biopsy on autosensitization against spermatozoal antigens. *Clin. Exp. Immunol.*, **18**: 201, 1974.

